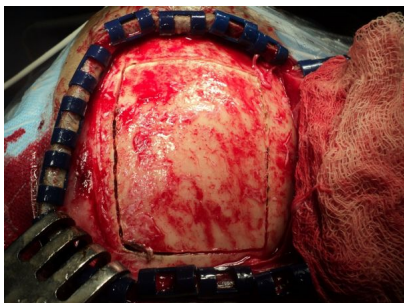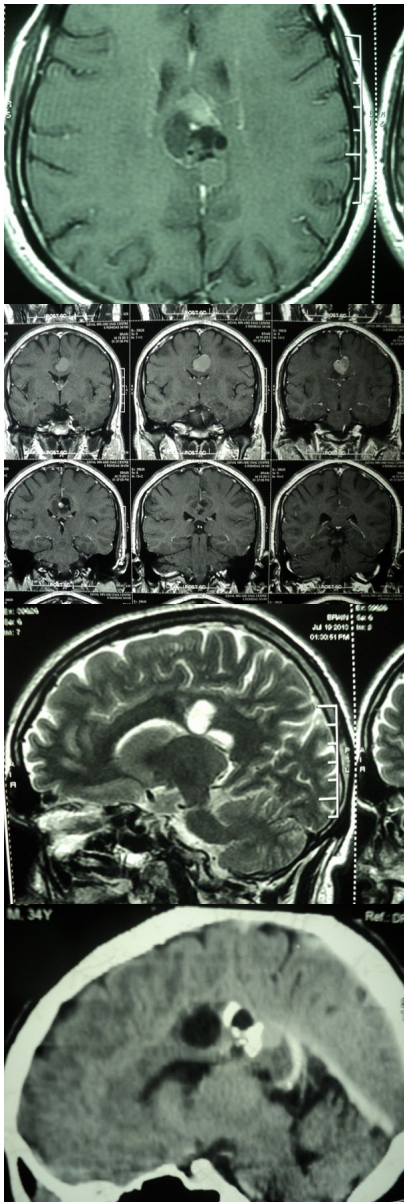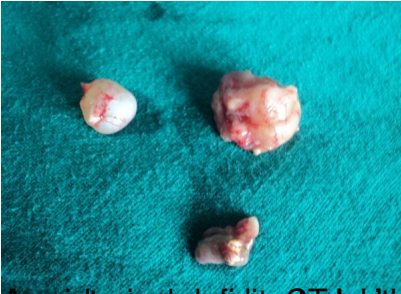


Lesion over body of corpus callosum



Key original paper: [Chen et al. Neurosurg Focus 2014;36\(1\):E1](#). [Mitsuda et al. J Neurosurg 2014;120\(1\):104-110](#). [Wang et al. J Neurosurg 2014;120\(1\):111-117](#). [Chen et al. J Neurosurg 2014;120\(1\):118-124](#).